

Rapid Fire Grand Ward Round



Dr Clarissa Cheng
15 July 2010

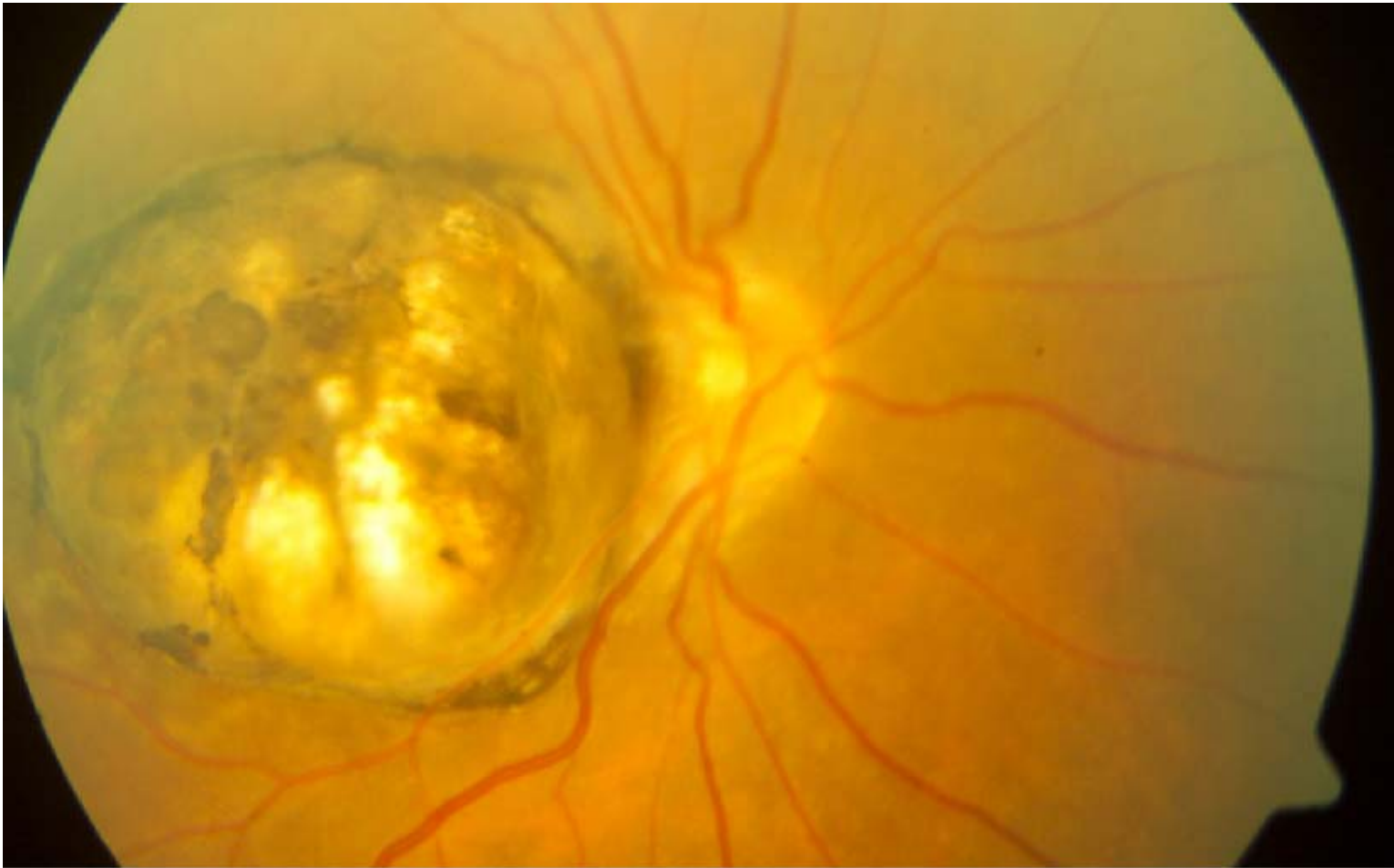
TTSH GRAND ROUNDS

Case 1

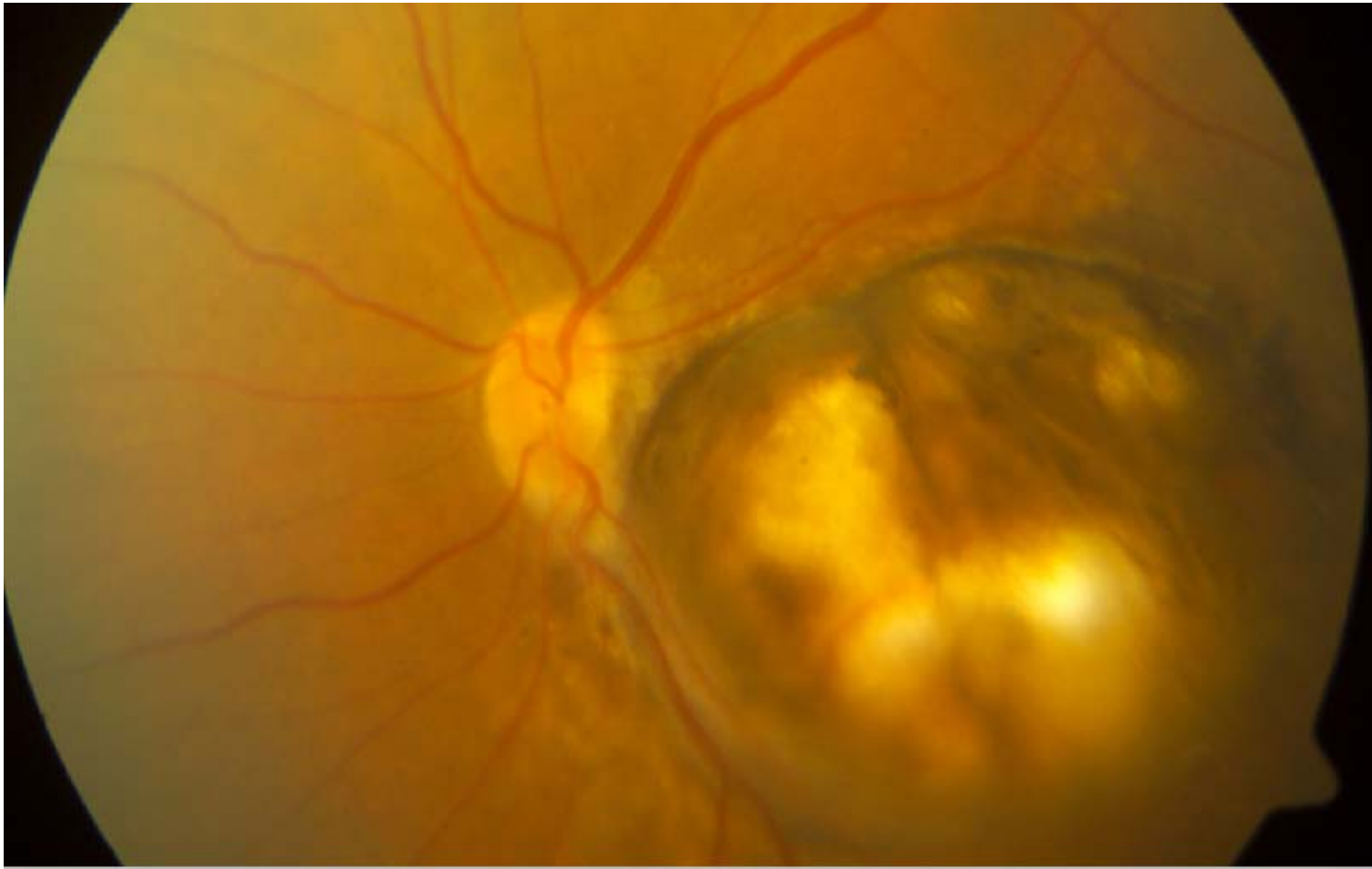
- 49-year-old Chinese female
- No past medical history
- Regular follow-up for cataracts and MGD

	<u>Right</u>	<u>Left</u>
VA	6/21	6/24
IOP	14	16
Lids	MGD	
Conjunctiva	White	
Cornea	Clear	
AC	Deep/Quiet	
Pupils	No RAPD	
Lens	NS1+	NS+
Retrolental	Quiet	

RE



LE



TTSH GRAND ROUNDS

Coloboma

Absence of a part of an ocular structure as a result of incomplete closure of the embryonic fissure.

Complete coloboma or part coloboma

Uncommon

Uni- or bi-lateral

Sporadic in an otherwise well individual or part of a syndrome.

Systemic associations:

- **Chromosomal abnormalities:** Patau syndrome (trisomy 13), Edward syndrome (trisomy 18) and Cat-eye syndrome (trisomy 22)
- **CHARGE:** Coloboma, Heart defects, choanal Atresia, Retarded growth and development, Genital and Ear anomalies
- **Others:** Meckel-Gruber, Goltz, Walker-Warburg, Goldenhar, Aicardi, Dandy-Walker cyst and linear sebaceous naevus, Treacher Collins, amniotic band syndrome
- **CNS anomalies**

Eyelid

- Upper lid: Junction of middle and inner third
- Lower lid: Junction of middle and outer third

Iris

- Inferonasal

Lens

- Notching (segmental agenesis) of the inferior equator with corresponding absence of zonular fibres

Retina and choroid

- Sporadic in otherwise normal individuals
- Sharply circumscribed, white area, largely devoid of blood vessels.
- Inferior fundus
- May involve optic disc if large and cause leukocoria
- **Complications:** retinal detachment

Optic Disc

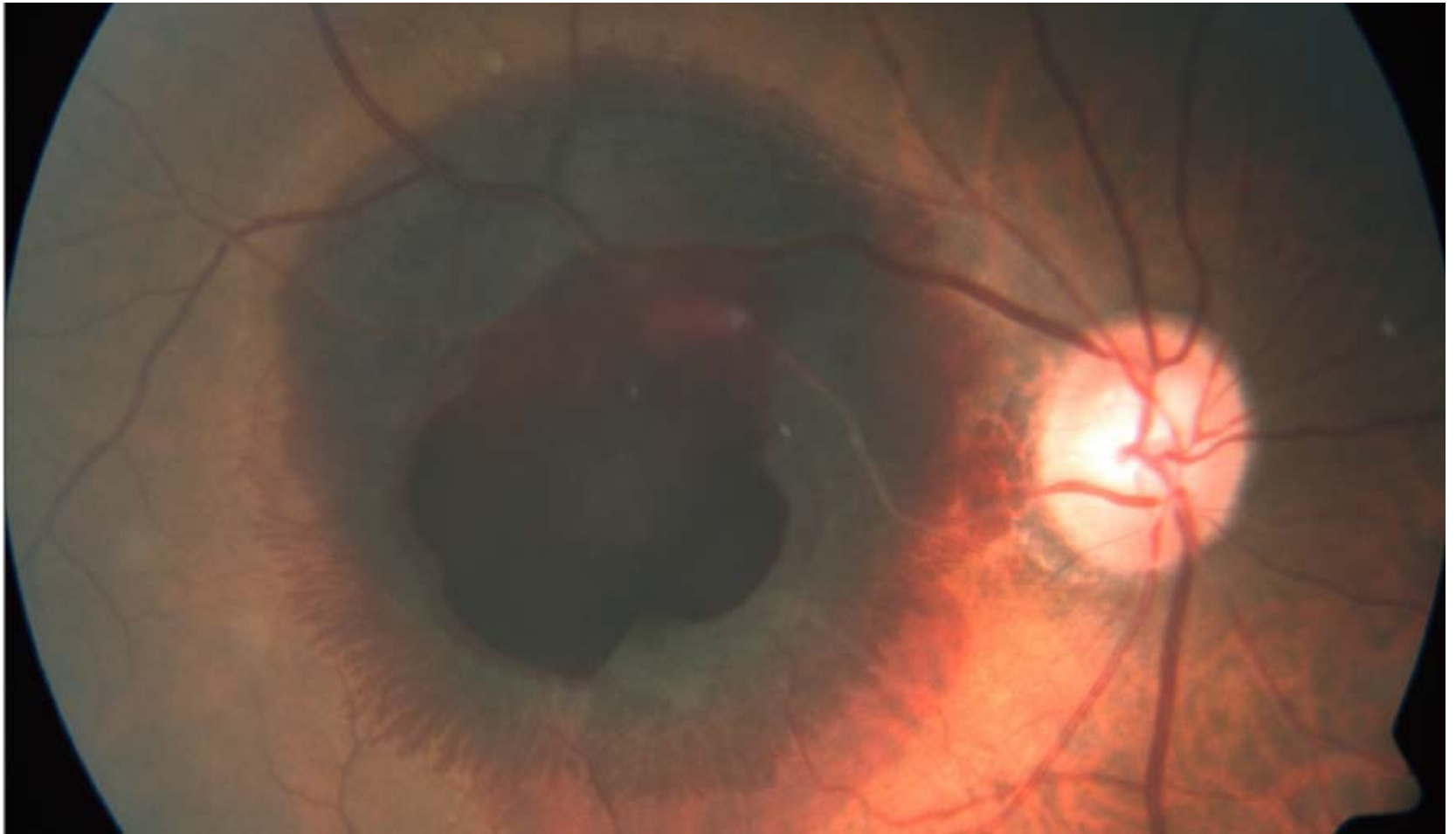
- Sporadic or AD inheritance
- VA decreased
- Discrete, focal, glistening, white, bowl-shaped excavation, decentred inferiorly
- Inferior neuroretinal rim thin or absent with corresponding superior defect on HVF
- **Complications:** CSR, progression despite normal IOP, peripapillary CNV

Case 2

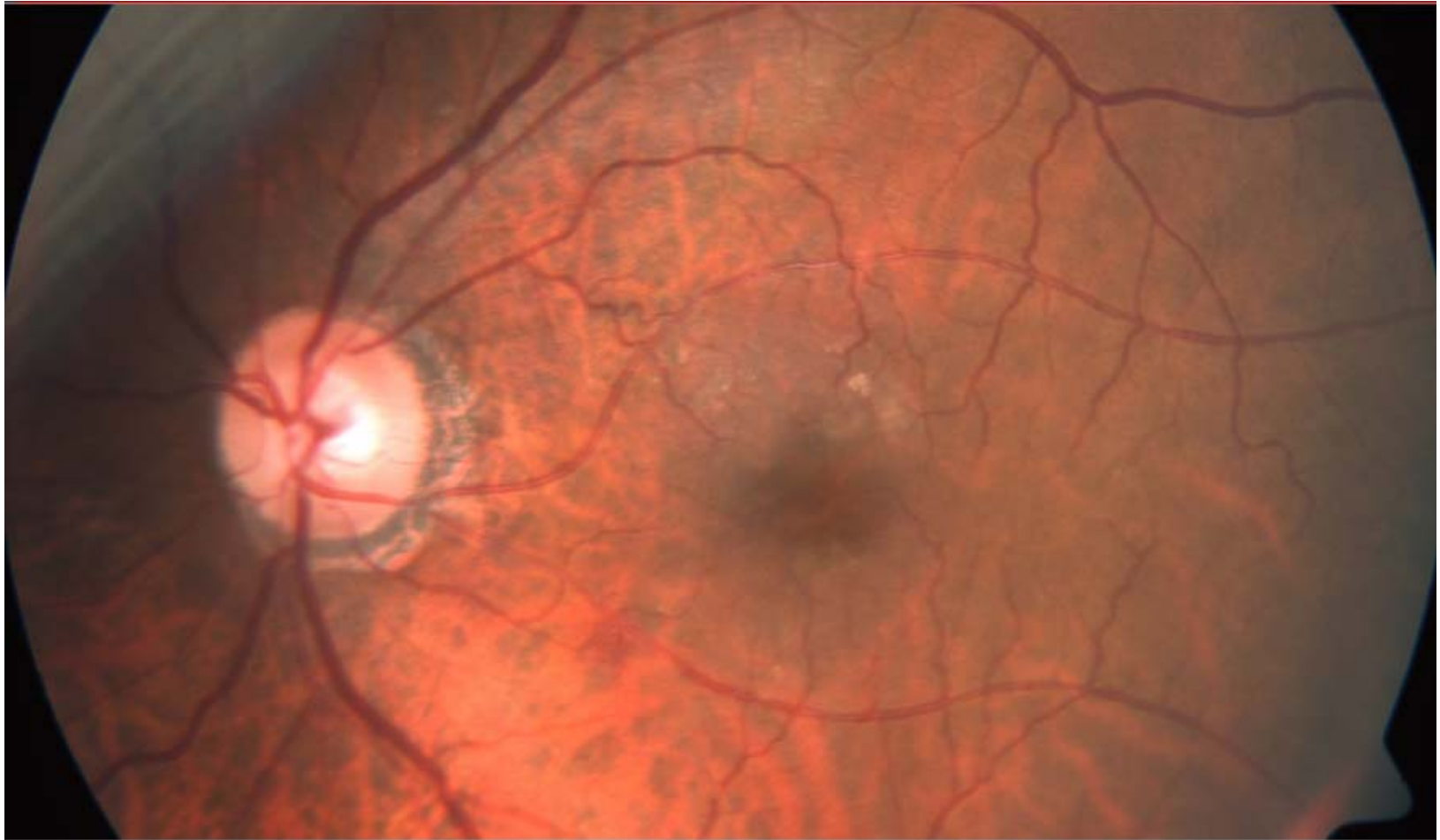- 88-year-old Chinese male
- Past medical history:
 - Hypertension and hyperlipidaemia on diet control
 - No DM/IHD/CVA, Non-smoker
- Past operation:
 - R/L cataract surgery > 10 years ago
- Complaint of: RE sudden loss of vision x 2-3 weeks ago
- No floaters or flashes

	<u>Right</u>	<u>Left</u>
VA	CF closely	6/15
IOP	13	13
Lids	MGD	
Conjunctiva	White	
Cornea	Clear	
AC	Deep/Quiet	
Pupils	No RAPD	
Lens	PCIOL	PCIOL
Retrolental	Quiet	

RE



LE



TTSH GRAND ROUNDS

Retinal artery macroaneurysm

Localized dilatation of a retinal arteriole which usually occurs in the first 3 orders of the arterial tree.

Demographics

Elderly

Hypertensive

Female

Presentation

1. **Insidious** impairment of central vision (leakage involving the macula)
2. **Sudden** loss of vision

Signs

Saccular or fusiform arteriolar dilatation.

Bifurcation or an arteriovenous crossing along the temporal arcades

50% associated with retinal haemorrhage

Multiple macroaneurysms along the same or different arterioles may be present

FA

- Typically, immediate uniform filling of the macroaneurysm with late leakage.
- Incomplete filling is due to thrombosis

Course

- **Chronic leakage:** retinal oedema with accumulation of hard exudates at the fovea with resultant loss of vision
- **Rupture:** with haemorrhage that can involve all layers of the retina (subretinal, intraretinal, preretinal and vitreous)
- **Spontaneous involution:** common and follows thrombosis and fibrosis. May precede or follow leakage or haemorrhage

Management

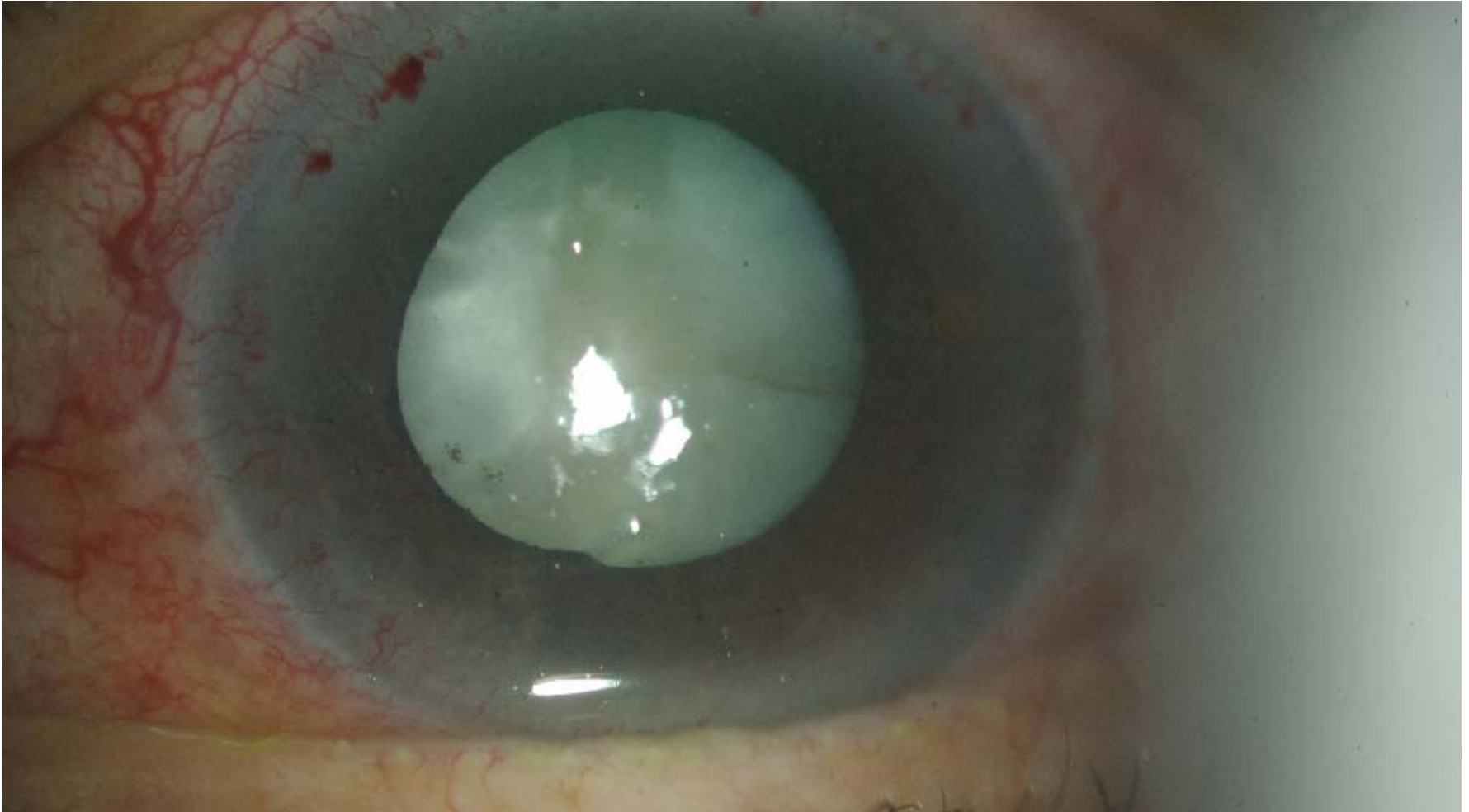1. **Observation:** good visual acuity, macula not threatened, mild retinal haemorrhage without significant oedema or exudation
2. **Laser photocoagulation:** oedema or hard exudates threaten or involve the fovea, particularly if there is visual deterioration.
3. **YAG laser hyaloidotomy:** large non-absorbing preretinal haemorrhage overlying macula
4. **Intravitreal injection:** submacular haemorrhage with gas, posturing and +/- tPA.

Case 3

- 70-year-old Chinese female
- Past medical history:
 - Hyperlipidaemia
- Presented with: LE pain, redness and blurring of vision x 1/12
- Associated with halo and glare on and off
- No headache, nausea or vomiting

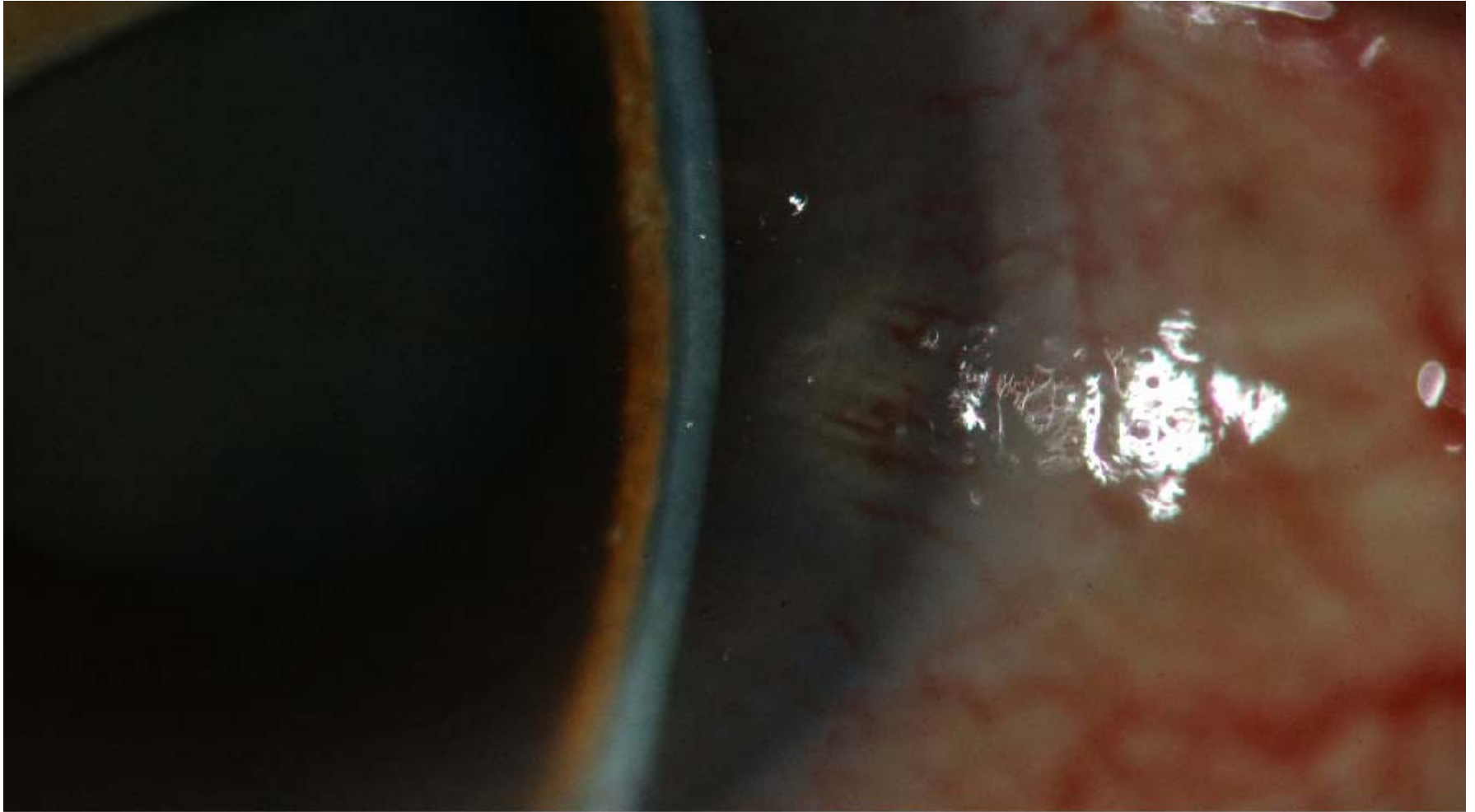
	<u>Right</u>	<u>Left</u>
VA	6/12	PL PL PL PL
IOP	20	60
Conjunctiva	White	Injected
Cornea	Clear	Hazy, microcysts
AC	Shallow	Flat
VH	1	0
Pupils	Reactive	Dilated pupil, reverse RAPD +
Lens	NS2+	Intumescent

LE



TTSH GRAND ROUNDS

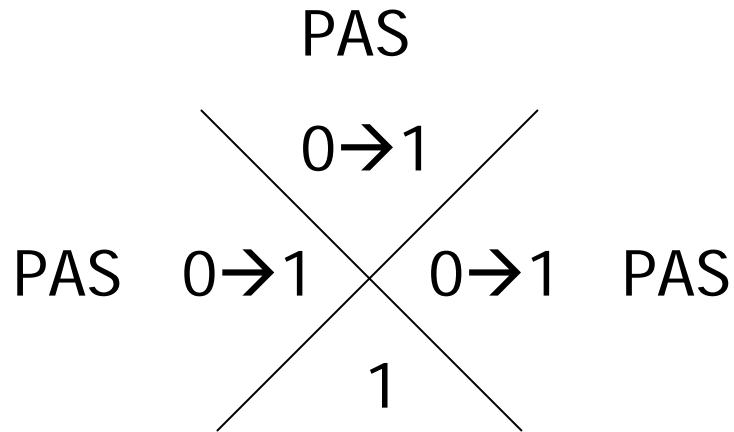
LE




TTSH GRAND ROUNDS

- Gonioscopy

RE



LE



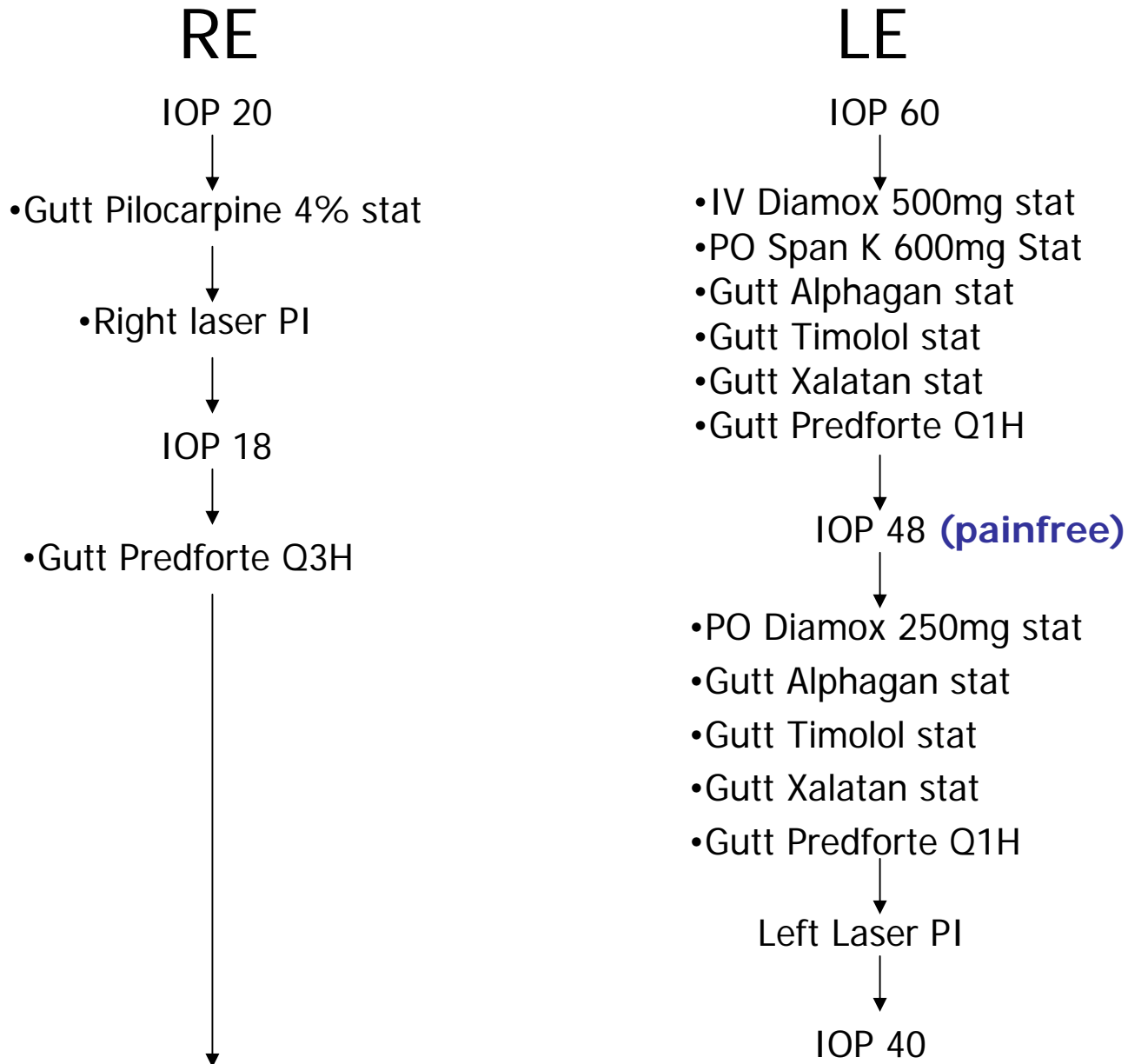
- B-scan

- Mild vitreous opacities
- Marked, deeply cupped disc
- Retina flat
- No mass lesion

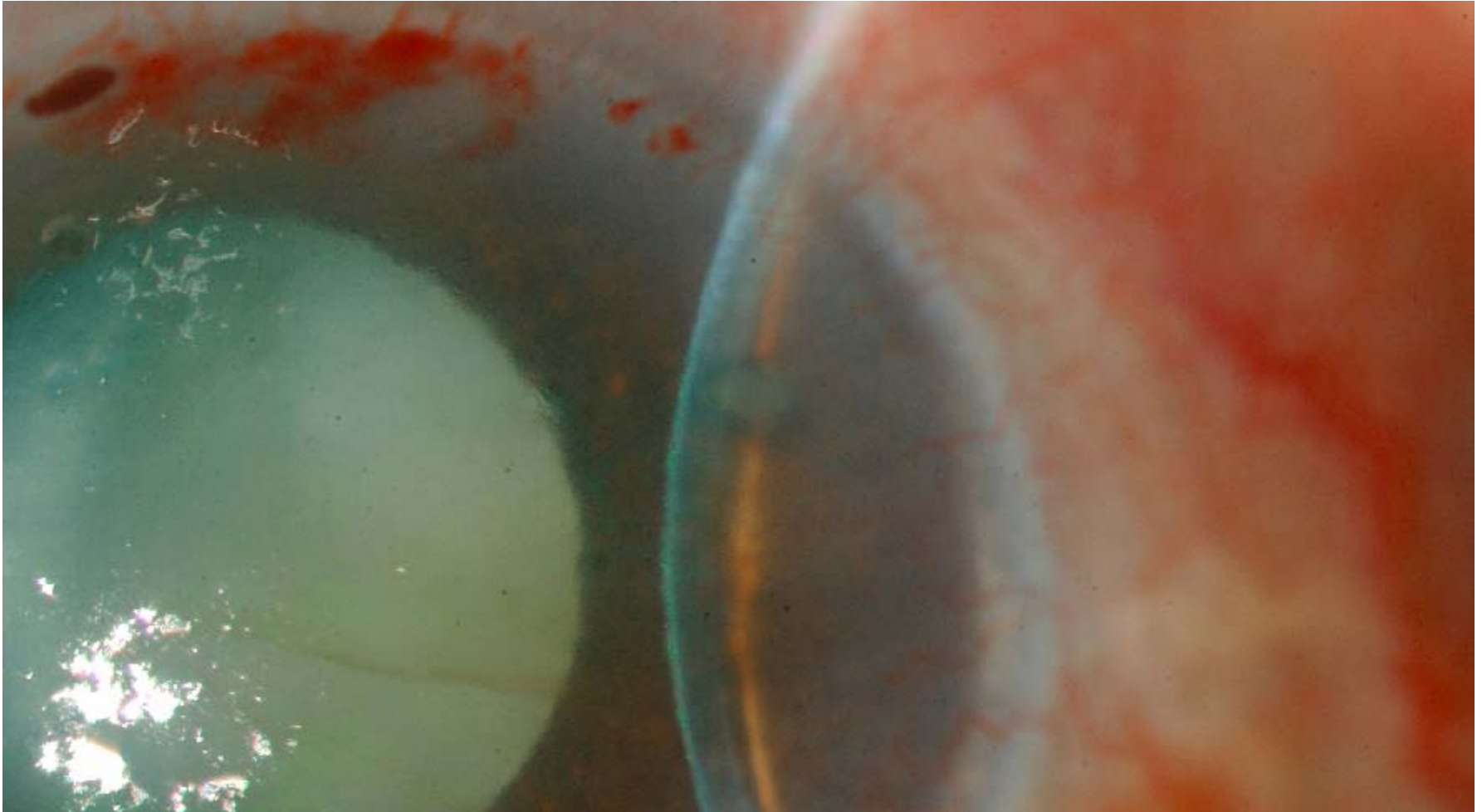
Diagnosis

1. Left phacomorphic glaucoma and neovascular glaucoma
 - ? Ischaemic CRVO
2. Right PACS

Management



LE Post LPI



Management

RE

IOP 13



- Gutt Predforte Q3H

LE

IOP 48



- PO Diamox 250mg TDS
- PO Span K 600mg OM
- Gutt Alphagan TDS
- Gutt Timolol BD
- Gutt Xalatan ON
- Gutt Predforte Q1H

Discharged with medication, TCU 1/52

IOP 20



DRE: CDR 0.8

Gutt Timolol BD started

↓ Gutt Predforte QDS x 1/52 → stop

IOP 42



Decision made for 270° TCP

Management

RE

LE

LE 270° TCP

IOP 16



- Gutt Timolol BD

IOP 44, 40, 38



- Gutt Timolol BD
- Gutt Xalatan ON
- Gutt Predforte QDS
- Gutt Cravit QDS

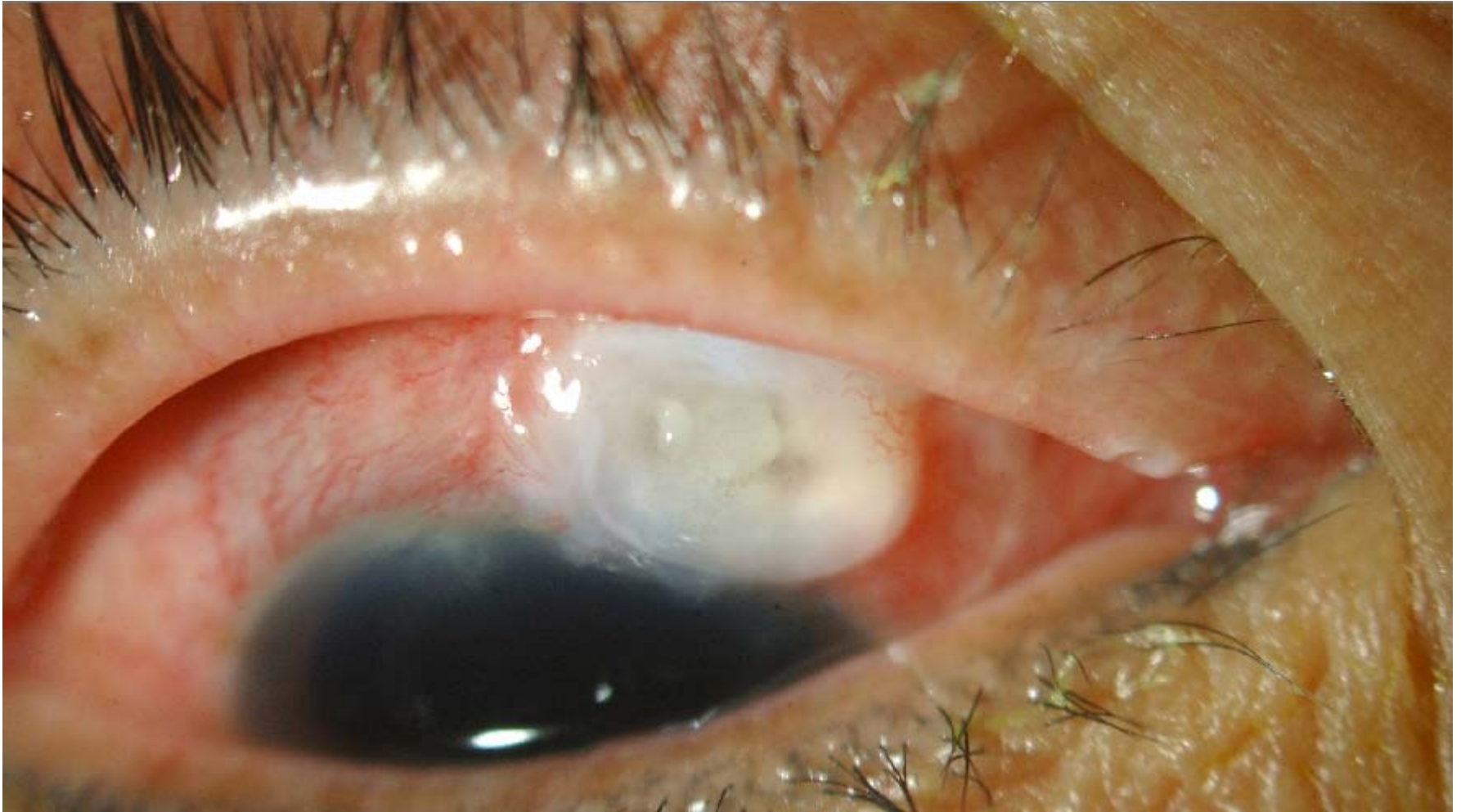
TCU 1/12 VA HVF DRE

Case 4

- 59-year-old Chinese female
- Transferred from another local hospital
- Past medical history: Hyperlipidaemia on diet control
- Past operations:
 - Left Phaco/Trab/IOL May 2007
 - Right Phaco/Trab/IOL Aug 2007
- Presented with RE redness and pain x 1/7

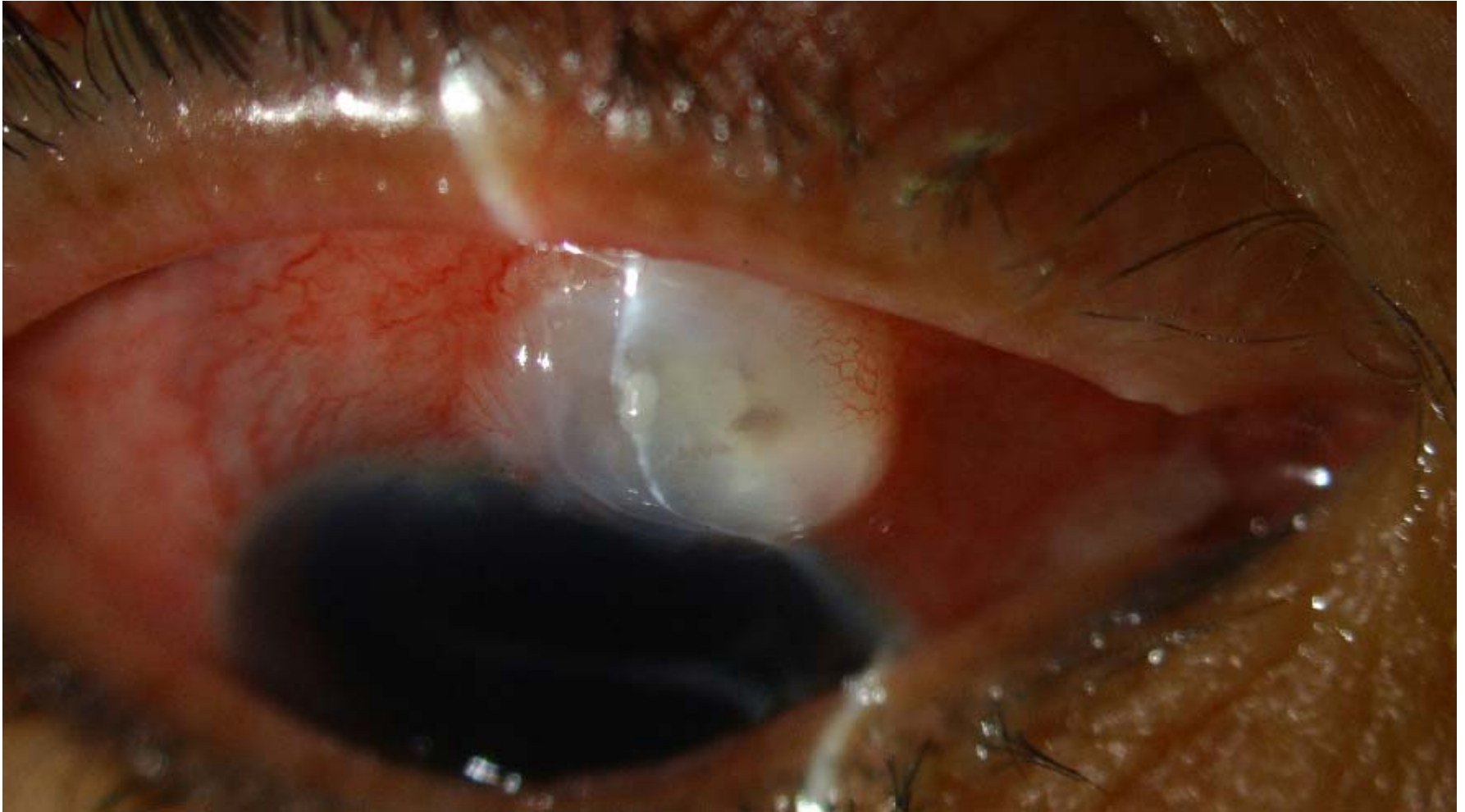	<u>Right</u>	<u>Left</u>
VA	6/12	6/7.5
IOP	4	16
Lids	MGD	
Conjunctiva	Injected	White
Cornea	Clear, DM folds	Clear
AC	1+ cells, no fibrin, no hypopyon	D/Q
Pupils	No anisocoria, no RAPD	
Lens	PCIOL	PCIOL

RE



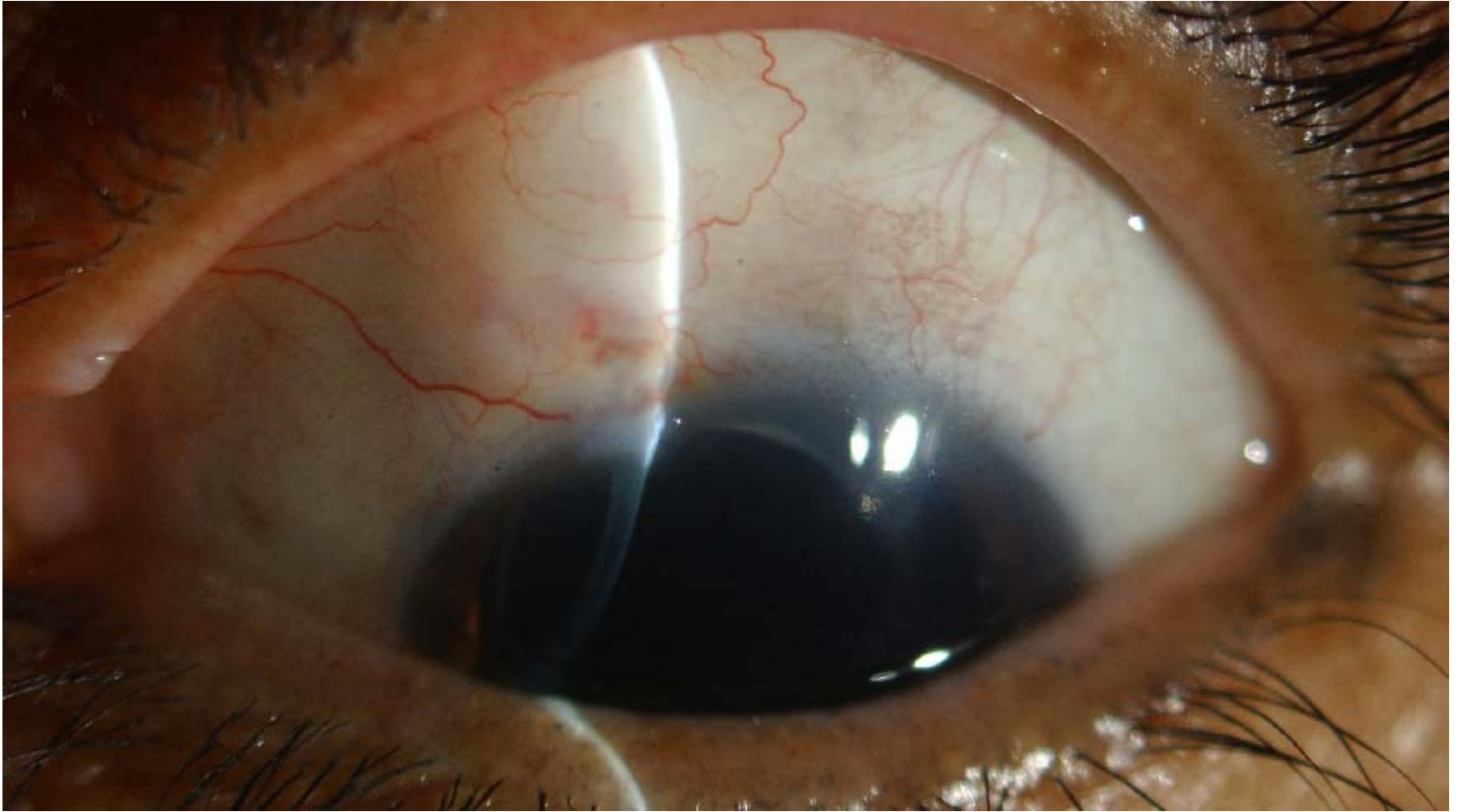
TTSH GRAND ROUNDS

RE



TTSH GRAND ROUNDS

LE



B-Scan: (gentle, through the lid)

- Very mild opacities with PVD
- No RD
- Choroidal (-)

	<u>Right</u>	<u>Left</u>
Posterior segment	Normal, no vitritis, no choroidal folds	Normal
Disc	0.5 Healthy rims	0.65 Bayonetting, inferior rim loss

Diagnosis

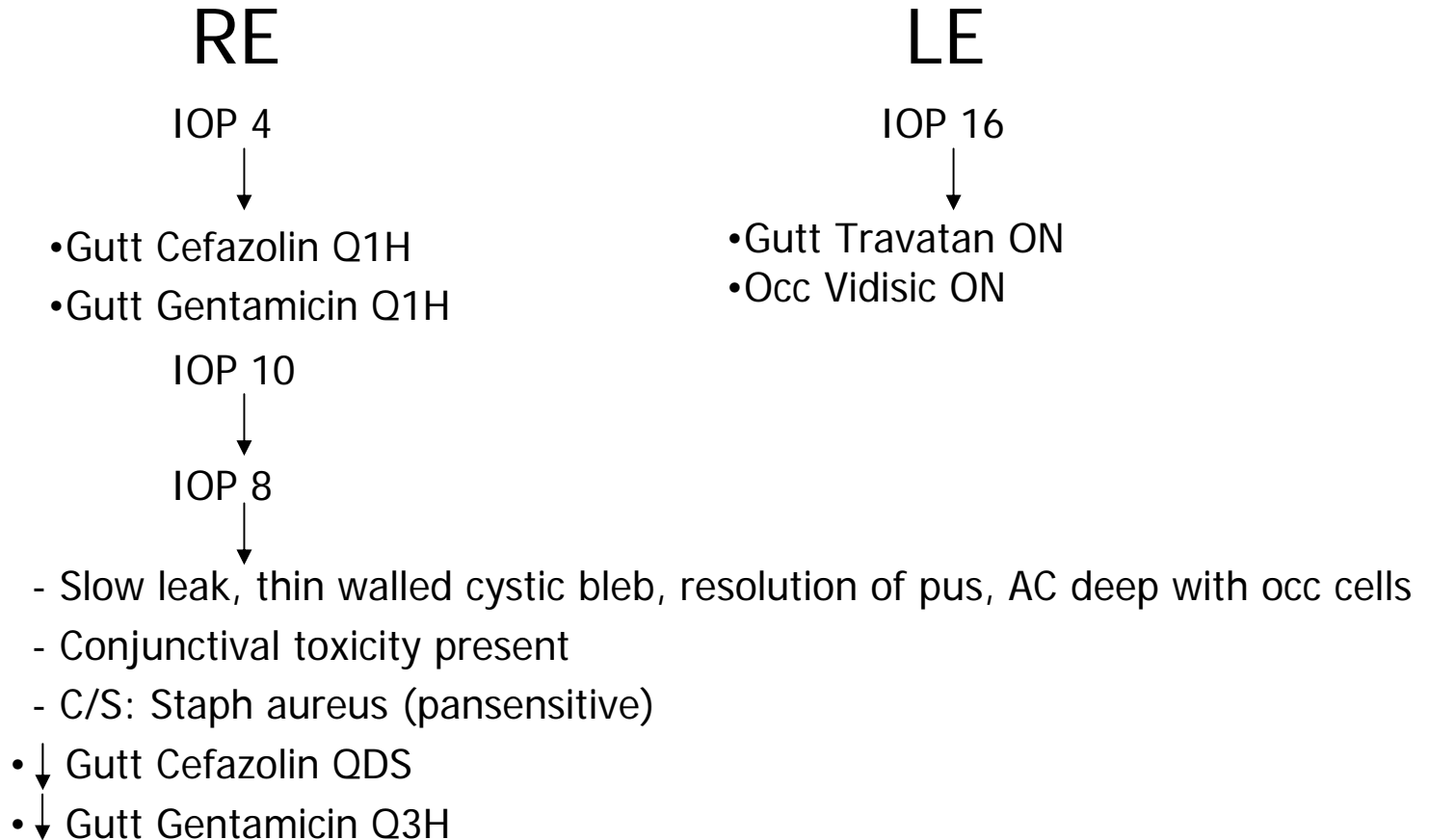
1. R blebitis and bleb leak
 - No posterior segment involvement

2. R/L CACG s/p Phaco/Trab 2007

Management

- Conjunctiva swabbed for gram stain and culture
- Patient admitted
- Gutt Vigamox Q2H started at the other local hospital stopped
- Fortified gutt cefazolin and gentamicin Q1H started

Progress



Discharged. TCU 1/7

Progress

IOP 4



- Slow leak, thin walled cystic bleb, no pus, AC deep with occ cells
- Conjunctival toxicity present
- Gutt cefazolin and gentamicin stopped
- Started gutt Cravit QDS, occ Fucithalamic BD and PO doxycycline 200mg OM

IOP 6



- ↓ Start gutt Cravit TDS
- cont occ Fucithalamic ointment BD and PO doxycycline 200mg OM
- Started gutt FML TDS

IOP 6



- Improved conjunctival redness
- Cystic bleb with a small focal point of leakage, no pus, AC deep with very occ cells
- Medications continued

TCU 2/52 VA DRE

Mac I, Soltau JB. *Curr Opin Ophthalmol.* 2003 Apr;14(2):91-4.

- **Trabeculectomy with mitomycin**

- Incidence of blebitis = 5.7% per year
- Incidence of endophthalmitis 0.8-1.3% per year

- **Pathogens:**

- **Early onset:**

- **coagulase-negative Staphylococcus sp.**
- **Propionibacterium acnes**
- **Staphylococcus epidermidis,**

- **Late-onset:**

- **Streptococcus sp.**
- **gram-negative bacteria e.g. Haemophilus influenzae**

- **Risk factors**

- **Location:** inferior or nasally (7.8% per patient year incidence of endophthalmitis)
- **Late-onset bleb leakage:** bleb-related infections were 26x as likely to have a bleb leak
- **Use of anti-fibrotic agent:** greater rate of late-onset bleb leaks (**MMC>5-fu**)
- **High bleb**
- **Blepharitis**
- **Intermittent or chronic use of topical antibiotics:** selection of virulent bacteria?
- Trabeculectomy alone v trabeculectomy with cataract extraction
- Others: Systemic corticosteroids, juvenile glaucoma, silk conjunctival sutures, nasolacrimal duct obstruction, releasable sutures, pale-coloured blebs, contact lens wear, bleb-revision surgery, male, younger age at surgery, black race.

Surgical Revision of Filtration Blebs: A Follow-up Study

van de Geijn EJ, Lemij HG, de Vries J, de Waard PW. J Glaucoma. 2002 Aug;11(4):300-5.

- Retrospective analysis of 36 consecutive cases of leaking, overfiltrating, or oversized blebs treated with bleb excision and conjunctiva and Tenon advancement in a glaucoma referral center between January 1991 and December 1999.
- Follow-up: 12 months to an average of 29.5 months
- All surgical glaucoma filtering procedures had been done in the superior bulbar quadrants
- **Bleb leak complicated by blebitis n = 10**
 - 1 had bleb-related bacterial endophthalmitis 2 years earlier
 - 7 had prior unsuccessful bleb interventions e.g. autologous blood injection for hypotony maculopathy (n=5), needle incision at the slitlamp and Nd:YAG laser of an oversized bleb (n=1), autologous blood injection for bleb leak and cataract extraction and IOL implantation (n=1)
- Managed inpatient n = 6
 - 5 IV cephazolin and gentamicin, topical fortified cephazolin and gentamicin
 - 1 topical gentamicin, and intracameral gentamicin and vancomycin intra-op
- Managed outpatient n = 4
 - Topical cephazolin and/or gentamicin and topical steroids 12-24 hours later

TABLE 3. Outcome of the successful bleb revisions

Patient	IOP (mm Hg)			Target	Pretrab meds§	Final meds	Trab-revision interval (mo) [#]	Follow-up (mo)
	Pretrab	Prerevision†	Final‡					
Leak								
1	16	5	18	No	2	2	18	16
2	29	7	12	Yes	2	1	13	19
3	27	7	15	Yes	2	2	8	58
4	21	0	12	Yes	2	2	156	34
5	23	4	14	Yes	2	3	27	20
6	21	0	12	Yes	2	2	37	18
7	18	2	13	Yes	3	2	93	17
8	20	5	21	Yes	1	0	12	15
9	24	6	20	Yes	2	0	32	16
10	32	10	11	Yes	3	0	37	17
11	33	7	13	Yes	1	0	32	16
12	25	3	7	Yes	3	0	50	24
13	21	6	18	Yes	1	1	65	21
Blebitis								
14	15	4	10	Yes	1	0	25	30
15	31	0	12	Yes	3	2	20	21
16	24	5	10	Yes	1	0	21	22
17	20	2	13	Yes	3	2	156	23
18	18	0	20	Yes	3	0	21	69
19	24	2	16	Yes	3	0	16	19
20	24	0	17	Yes	2	0	43	35
21	14	5	12	Yes	2	1	7	31
22	20	14	16	Yes	2	1	42	17
Maculopathy								
23	25	1	12	Yes	2	0	21	15
24	27	5	11	Yes	2	1	33	40
25	24	0	18	Yes	3	0	60	30
26	36	2	6	Yes	2	0	105	27
27	23	4	18	No	4	3	13	12
28	18	3	8	Yes	1	0	26	89
29	40	6	11	Yes	2	1	23	40
Large bleb								
30	22	14	11	Yes	1	0	23	
31	19	8	11	Yes	2	0	6	
Mean	23.7	4.3	13.5		2.1	0.8	40	
SD	5.9	3.7	3.8		0.8	1.0	37.9	
Range					1-4	0-3	7-156	1-...

Success: n=9

Failure: n=1

|| IOP, intraocular pressure.
 † Last IOP before the original trabeculectomy. ‡ Last IOP before revision surgery.
 ‡ IOP at last follow-up visit.
 § Number of antiglaucoma medications before the original trabeculectomy.
 || Number of antiglaucoma medications at last follow-up visit.
 # Interval between the original trabeculectomy and first revision surgery.

Surgical success = final intraocular pressure between 6 and 22 mm Hg with or without topical antiglaucoma medication, resolution of the bleb leak, hypotony maculopathy and symptoms, and no need for repeat glaucoma surgery.

- **Conclusion:**

- Good definitive solution that provides satisfactory IOP control for bleb related complications
- 86.1% overall success rate
 - 90% bleb leak complicated by blebitis

- **Limitations:**

- Retrospective
- Limited sample size
- Short follow-up
- No control group
- Different antibiotic treatment regime
- Unknow duration of antibiotic treatment
- Possible bias from previous treatment.

Thank You